

# Clinical Manifestation of Clear Cell Hidradenoma at Neck: a Rare Case of Tumor of Duct Origin of Sweat Gland

Chaichana Chantharakhit, M.D.

Medical Oncology Unit, Department of Medicine, Buddhasothorn Hospital, Chachoengsao Province, Thailand.

**Abstract:** Clear cell hidradenoma is a rare benign tumor of skin and reports of clinical manifestation are quite limited. We report a 35-year-old Thai male who presented at Buddhasothorn Hospital, Chachoengsao Province, with recurrent tumor on the neck. The patient was treated with total surgical removal of the tumor. Pathological studies showed that the intradermal tumor cell was composed of 2 cell populations, polygonal-shaped clear cells and round cells. Small ductal structures were rarely seen. Mitotic features were not identified. The tumor was partially stained with EMA. CEA failed to highlight the ductal component. The stains for S-100, Ber-EP4, RCC and CD34 were negative. These results were consistent with clear cell hidradenoma. The patient was not given any postoperative adjuvant treatment. No recurrence was detected at a follow-up visit 5 months after the operation.

**Key words:** clear cell hidradenoma, clinical manifestation

## Introduction

Hidradenoma is a cutaneous tumor of the sweat glands.<sup>(1,2)</sup> This tumor is benign in nature; and it is also known as solid cystic hidradenoma and acrospiroma. It is a rare benign tumor commonly seen as solitary skin-colored nodule in adults more frequently found in female.<sup>(3)</sup> The usual locations of this tumor are on the scalp, face, anterior trunk and proximal limbs.<sup>(4)</sup> Although it is a benign tumor, malignant transformation has been observed. In such case, it is characterized by rapid growth and cutaneous ulceration of which histological examination will be will

reveal an increased number of mitotic figures, nuclear atypia and angiolymphatic or perineural invasion; and aggressive management is required in order to reduce the risk of recurrence and malignant transformation.<sup>(5)</sup>

Due to the rare incidence of hidradenoma, reports and literature reviews on clinical manifestations of this disease are quite limited. In this case report, clinical manifestation of a patient with clear cell hidradenoma on the neck is described. The patient was diagnosed at the Medical Oncology Unit, Department of Medicine, Buddhasothorn Hospital, Chachoengsao province, Thailand.

### Case Report

A 35-year-old male sought a consultation at a district hospital with the complaint of recurrence occurrence of a tumor located at occipital bone of the neck since 2012. During that first consultation he was diagnosed as a benign tumor; and no medication was provided. In 2014, due to the tumor progression, the patient went to the same district hospital for another consultation; and surgical removal of the tumor was performed without histo-pathological study of the tissue specimen.

In the early 2016, a tumor had been noticed at the backside of the occipital bone close to near the original position; and it began to grow but slightly movable and painless. The patient decided to seek medical attention at the provincial health facility, Buddhasothorn Hospital, Chachoengsao province. Upon the physical examination, it was easily palpable with the size of approximately 1 cm in diameter. The tumor was surgically removed in September 2016, and the specimen was sent for histological examination.

The histopathological studies reported that the tumor was comprised of a few intradermal solid-cystic

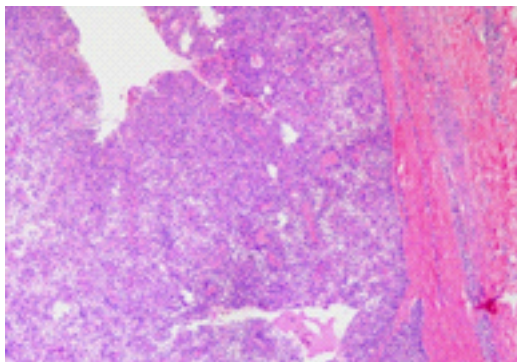
nodules with well-circumscribed borders and non-capsulated. Microscopic examination revealed the tumor tissue to compose of small pale eosinophilic cells and large clear cells arranged in solid pattern. Focal duct-like structures were observed, but not prominent. Each cell was rather uniform, round, normochromatic nuclei with small inconspicuous nucleoli. Mitotic figure was not detected. The surrounding stroma was hyalinized fibrovascular tissue. The overlying epidermis and subcutaneous tissue were not remarkable. Morphologically, it was suggestive of adnexal eccrine/apocrine tumor, and favoring benign.

Investigation using immunohistochemical stains revealed the following findings:

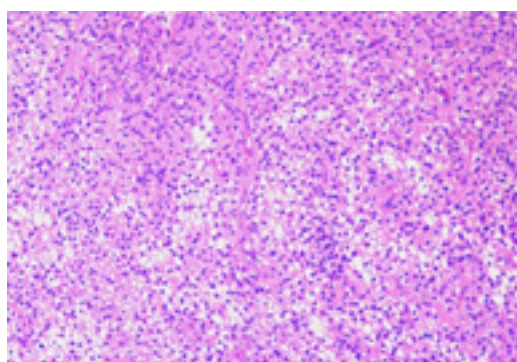
- S-100 immunohistochemical marker negative;
- Epithelial membrane antigen (EMA) positive;
- Carcinoembryonic antigen (CEA) negative;
- Basal cell carcinoma indicator (Ber-EP4) negative;
- Renal cell carcinoma (RCC) antigen negative;
- Transmembrane phosphoglycoprotein (CD34) negative.

Histopathological image and description was showed in Figures 1 to 7.

**Figure 1** The deep intradermal tumor showed well demarcation between the neoplastic border and dermis. Intratumoral cystic degenerations were observed.



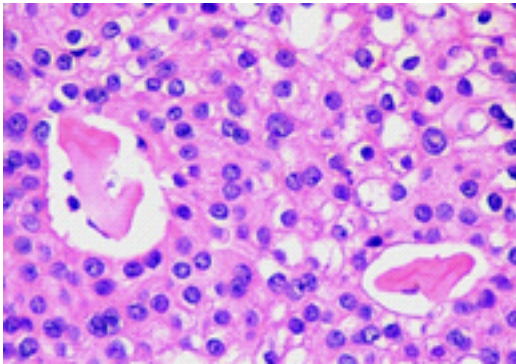
**Figure 2** The tumor was composed of 2 cell populations, clear cells and eosinophilic cells. Delicaded feeding vessels was observed.



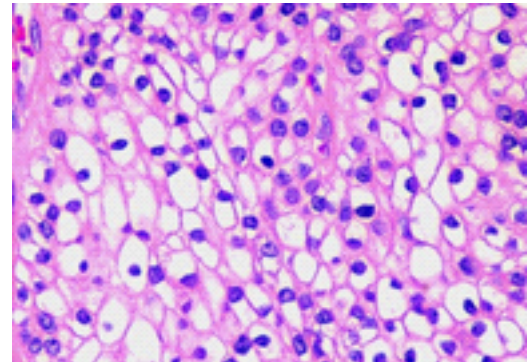
The final diagnosis was clear cell hidradenoma; and complete excision was suggested. The patient was advised to attend a local health facility for the care of his surgical wound; and appointment for follow-up to

Buddhasothorn Hospital for post-surgical check-up. At 5 months after the operation, no tumor recurrence was detected.

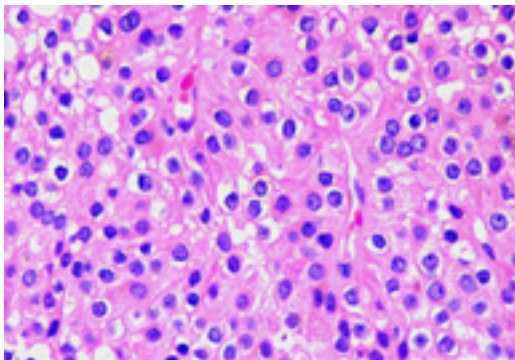
**Figure 3** Small ductal structures were rarely seen showing eosinophilic secretion within the lumen. These features were supported for the eccrine/apocrine differentiation.



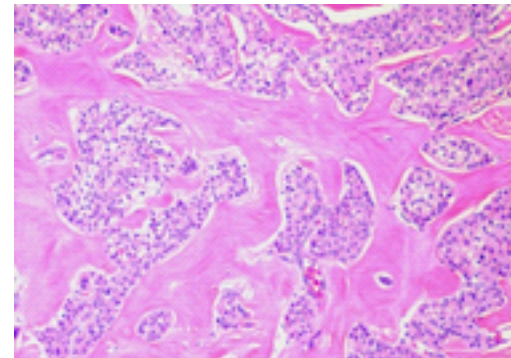
**Figure 4** Clear cell component showed polygonal-shaped cells within distinctly clear cytoplasm and rather uniform, round, normochromatic nuclei. Mitotic features were not identified.



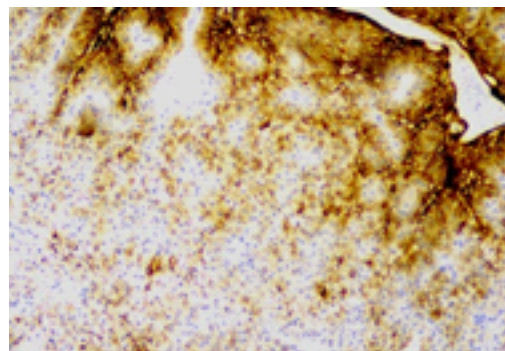
**Figure 5** Eosinophilic cell component is composed of polygonal-shaped cells with pale eosinophilic cytoplasm and rather uniform, round, normochromatic nuclei and small nucleoli. Mitotic features were not identified.



**Figure 6** The picture showed the neoplastic sclerotic stroma distinctly separate the tumor from the dermis.



**Figure 7** The tumor partly stained with EMA. CEA failed to highlight the ductal component. The stains for S-100, Ber-EP4, RCC and CD34 were negative.



## Discussion

Clear cell hidradenoma was firstly reported in 1949 by Liu Y.<sup>(6)</sup> Later, there were different reports in various names, such as nodular clear cell hidradenoma, clear cell myoepithelioma, eccrine sweat gland adenoma of clear cell type, eccrine acrospiroma or solid cystic hidradenoma. According to the reports in previous literatures,<sup>(7,8)</sup>

In this report, the tumor located at the occipital area of the neck in the form of a soft single lump. Based on the information from the patient, the tumor grew slowly without pain and not attached firmly with the underlying tissue. From the clinical manifestations, it was a benign tumor. However, differentiation with malignant tumors such as renal cell carcinoma was necessary,<sup>(8,9)</sup> which requires pathological examination and immunohistochemistry staining.

The main pathological characteristics of clear cell hidradenoma are a solitary nodule, unencapsulated dermal nodule and well circumscribed dermal tissue.<sup>(10)</sup>

It is most commonly found in the area of Grenz zone between layers of epidermis. Sometimes, it could be found in deeper subcutaneous fat layers. Morphologically, two common cell appearances are observed: (1) polyhedral cells with round nucleus with a basophilic cytoplasm characteristics, and (2) round-shaped cells with a clear cytoplasm characteristics, which is found in less than one-third of cases with clear cell hidradenoma. In addition, mucous-producing cells were detected in some patients. According to the reports in previous literatures, immunohistochemistry staining could obtain positive results for smooth muscle actin and muscle specific actin; negative result for dermis and S-100, and no mitosis. The immunohistochemistry staining was not examined in all patients unless

they were in need of definite diagnosis, particularly those with unclear clinical manifestation and pathological characteristics. Nonetheless, the recent study indicated that although clear cell hidradenoma is a benign tumor, but it can recur in case of inadequate excision.<sup>(8,11,12)</sup>

According to the clinical manifestation of the patient, his clinical and pathology findings were consistent with clear cell hidradenoma, which was in line with the description in the literature. Since the patient had a history of recurrence within 2 year, a long-term follow-up for examining tumor reappearance was recommended.

## Acknowledgement

*The author would like to express sincere thanks to Dr. Ulan Suankwan from Department of Anatomical Pathology, Buddhasothorn Hospital, for histopathological consultation of this case.*

## References

1. Bagga P, Shahi M, Mahajan N. Clear cell hidradenoma—a case report. *Internet Journal of Pathology* 2008;8:1–4.
2. Winkelmann RK, Wolff K. Solid-cystic hidradenoma of the skin. *Clinical and histopathological study. Arch Dermatol* 1968;97:651–61.
3. Kakinuma H, Miyamoto R, Iwasawa U, Baba S, Suzuki H. Three subtypes of poroid neoplasia in a single lesion: eccrine poroma, hydroacanthoma simplex, and dermal duct tumor. *Histologic, histochemical, and ultrastructural findings. Am J Dermatopathol* 1994;16:66–72.
4. Shahmoradi Z, Mokhtari F. Clear cell hidradenoma. *Adv Biomed Res* 2013;2:40.
5. Kailas KC, Nanjappa N, Srikantaiah HC. Hidradenoma: a skin adnexal tumour, case report and literature review. *J Pat Care* 2015;1:104.

6. Liu Y. The histogenesis of clear cell papillary carcinoma of the skin. *Am J Pathol* 1949;25:93-103.
7. Hernandez-Perez E, Cestoni-Parducci R. Nodular hidradenoma and hidradenocarcinoma: a 10-year review. *J Am Acad Dermatol* 1985;12:15-20.
8. Volmar KE, Cummings TJ, Wang WH, Creager AJ, Tyler DS, Xie HB. Clear cell hidradenoma: a mimic of metastatic clear cell tumors. *Arch Pathol Lab Med* 2005; 129:113-6.
9. Mir-Bonafe JM, Santos-Briz A, Gonzalez M, Fernandez-Lopez E. Nodular clear cell hidradenoma: a rare case with similarities to metastatic clear renal cell carcinoma. *F1000 Research* 2013;2:213:1-4.
10. Hernandez E, Cestoni R. Nodular hidradenoma and hidradenocarcinoma. *J Am Acad Dermatol* 1985;12:15-20.
11. Knoedler D, Susnik B, Gonyo MB, Osipov V. Giant apocrine hidradenoma of the breast. *Breast J* 2007;13:91-3.
12. Yildiz B, Ozdemir F, Cobanoglu U, Kavgaci H, Fidan E, Aydin F. Clear Cell Hidradenoma of the Gluteal Region: A Case Report. *Acta Dermatovenerol Croat* 2009;17: 144-6.

**บทคัดย่อ:** อาการแสดงทางคลินิกของผู้ป่วย Clear Cell Hidradenoma ที่คอ: ก้อนเนื้อออกจากเซลล์ท่อของต่อมเหงื่อชนิดที่พบได้ไม่บ่อย

ชัยชนะ จันทร์คิด พ.บ.

หน่วยมะเร็งวิทยา กลุ่มงานอายุรกรรม โรงพยาบาลพุทธโสธร จังหวัดฉะเชิงเทรา

วารสารวิชาการสาธารณสุข 2561;27:743-7.

เนื้ออกชนิด clear cell hidradenoma เป็นเนื้ออกของผิวหนังชนิดไม่รุนแรงที่พบน้อยมาก ข้อมูลรายงานเกี่ยวกับอาการทางคลินิกมีอยู่อย่างจำกัด บทความนี้วัตถุประสงค์เพื่อรายงานผู้ป่วยชายไทยอายุ 35 ปี ซึ่งมีอาการมีก้อนเนื้ออกโตขึ้นช้าที่บริเวณคอ เคยรับการรักษาในโรงพยาบาลชุมชนโดยการตัดเอาเนื้ออกออกไป แต่ก็เกิดเนื้ออกขึ้นใหม่ใน 2 ปีต่อมา ผู้ป่วยจึงเข้ารับการรักษาในโรงพยาบาลพุทธโสธร จังหวัดฉะเชิงเทรา ซึ่งตรวจพบเป็นก้อนเนื้อขนาดเส้นผ่าศูนย์กลาง 1 เซนติเมตรที่บริเวณด้านหลังของคอ ได้รับการรักษาโดยการตัดเอาก้อนเนื้ออกและส่งชิ้นเนื้อตรวจทางห้องปฏิบัติการ ซึ่งลักษณะทางพยาธิวิทยาเป็น intradermal tumor ที่ประกอบด้วยเซลล์รูปร่าง 2 ชนิดได้แก่ เซลล์รูปร่างหลายเหลี่ยมและเซลล์รูปร่างกลม พบเห็นลักษณะโครงสร้างท่อได้น้อย ไม่พบ mitosis ตรวจ immunohistochemistry พบให้ผลบวกต่อ EMA ให้ผลลบต่อ CEA, S-100, Ber-EP4, RCC, CD34 ผลทางพยาธิวิทยาสันนิษฐานวินิจฉัย clear cell hidradenoma และผู้ป่วยรายนี้ไม่ได้รับการรักษาเสริมหลังได้รับการผ่าตัด และจากการติดตามการรักษาหลังการผ่าตัด 5 เดือนไม่พบว่ามีเนื้ออกเกิดขึ้นมาอีก

**คำสำคัญ:** โรคมะเร็ง clear cell, hidradenoma, อาการแสดงทางคลินิก