

Efficacy and Safety of Periorbital Syringoma Treatment using Fractional Erbium YAG Laser

Jirot Sindhvananda, M.D.

Nataya Voravutinon, M.D.

Chandrapa Chandrangsu M.D., M.Sc.

Institute of Dermatology, Department of Medical Services, Bangkok, Thailand

Abstract Syringoma is a benign adnexal tumor of the skin, predominantly involving the periorbital areas which can cause significant cosmetic concerns for affected individuals. An ideal treatment of syringoma is selective destruction with little damage to the normal tissue which is literally impossible for the conventional treatment modalities. The fractional erbium-doped yttrium aluminum garnet (erbium YAG) laser utilized in this study is unique that it has adjustable depth and coagulation parameters. The objective of this study was to demonstrate the efficacy and safety of fractional erbium YAG laser for treating periorbital syringomas. Ten patients with biopsy-proven periorbital syringomas were treated with 3 sessions of fractional erbium YAG laser at 6-week interval. Clinical evaluation performed at 1, 3 and 6 months after last treatment using photographic comparison revealed grade 4 clearance in 7 cases and grade 3 clearance in 3 cases. The clinical improvement scores at 1, 3 and 6 months after the last laser treatment were significantly different ($p < 0.05$). Patient satisfaction was evaluated at 6 months post laser treatment with result of very satisfied in 4 cases and satisfied in 5 cases. No complications, such as scarring, erythema, and pigmentary changes, were observed. The authors concluded that the fractional Erbium YAG laser might be an alternative modality to treat periorbital syringoma to gain good cosmetic results without complications if applied repeatedly.

Key words: Syringoma, fractional laser, Erbium YAG laser, periorbital syringomas

Introduction

Syringoma is a common benign adnexal tumor of the skin that predominantly occupies periorbital areas in various depth of the dermis which can cause significant cosmetic concerns in affected individuals.⁽¹⁻⁸⁾ Although several treatment modalities have been proposed such as excision, electrocautery, cryosurgery, chemical peelings, topical atropine or tretinoin and

laser surgery, none of them are satisfactory due to their limitations and side effects including scarring, pigmentary changes and prolonged healing time. With these treatment modalities, injury margins tend to be imprecise resulting in under or over treatment. The former is associated with recurrence and the latter with scarring.^(1,3,6-9)

The fractional Erbium-doped yttrium aluminum

garnet (Erbium YAG) laser is a unique device that has adjustable depth and coagulation parameters. It can deliver high and low energy erbium pulses to sequentially vaporize and coagulate tissue. The long, low energy, sub-ablative pulses are longer than the thermal relaxation time (TRT) resulting in heat production that dissipates into surrounding tissue which could be useful in preventing intraoperative bleeding.¹⁰ The objective of this study was to assess the efficacy and safety of fractional Er:YAG laser in the treatment of periorbital syringomas.

Materials and Methods

Syringoma patients, with the age range of 21–60 years, Fitzpatrick skin types III–V were treated with 3 sessions of fractional Erbium YAG 2,940 nm device (ProFractional™, Sciton, Inc, Palo Alto, CA) at 6 week interval. The diagnosis of all patients was confirmed histopathologically prior to the treatment. Patients were excluded if they had undergone other treatments within the previous 6 months, had a history of using systemic isotretinoin within the previous 6 months, had a propensity for keloids, or were pregnant or immunosuppressed.

Prior to the procedure, a topical eutectic mixture of 2.5% lidocaine and 2.5% prilocaine (Astra Pharmaceuticals LP, Wayne, PA) was used as a local anesthetic, applied for 1 hour to the treatment sites under occlusion. Metallic scleral eye shields were placed to protect the eyes under local ophthalmic anesthesia with tetracaine 0.5% solution. Setting of 400–500 µm ablative depth, 11% treatment area, pitch 2.6 mm, coagulation level 0–1 (predicted increase of 50 µm in depth) were used. The laser fluences were delivered in 2 passes over the periorbital area lesions.

The ablative depths and coagulation levels were adjusted according to lesion sizes and skin types. The postoperative wounds were managed with normal saline and terramycin ointment for dressing. Patients were advised to avoid exposure to sunlight and apply sunscreen. Patients presented with post-inflammatory hyperpigmentation would be treated with 3% hydroquinone cream nightly between sessions.

Clinical improvement was measured by pre- and post-clinical photographs taken at baseline, 1, 3 and 6 months after the last laser treatment. The clinical improvement scores were graded by 2 dermatologists blinded to the treatment, using a global improvement scale as follow:

- Grade 1 = 0% – 25% clearance of all lesions
- Grade 2 = 26% – 50% clearance of all lesions
- Grade 3 = 51% – 75% clearance of all lesions
- Grade 4 = >75% clearance of all lesions

Patients were asked to rate their overall satisfaction level, using a scale from 1 – 4 as follow:

- 1 = 0% – 25% improvement or otherwise unsatisfied;
- 2 = 26% – 50% improvement or slightly satisfied
- 3 = 51% – 75% improvement or satisfied
- 4 = more than 75% improvement or very satisfied

Adverse effects were identified by questioning patients and observing skin reactions, including erythema, edema, bleeding, infection, post inflammatory hyperpigmentation and scar.

Statistical Analysis

We compared clinical assessment scores and overall patient satisfaction levels at 1, 3 and 6 months after the last laser treatment using the nonparametric

Wilcoxon signed-rank test. Differences were considered statistically significant when $p < 0.05$.

Results

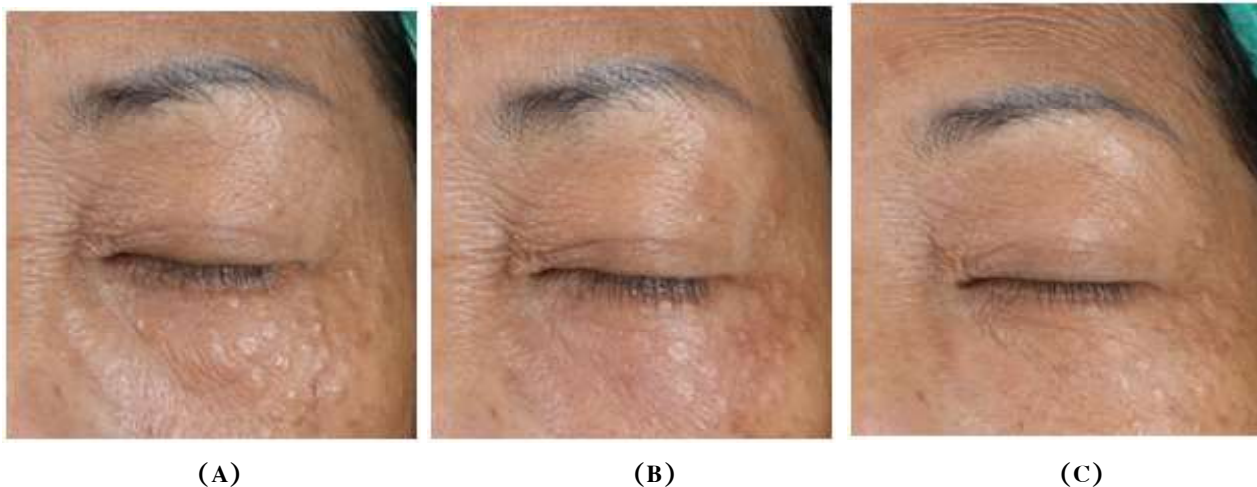
There were 10 patients recruited. All cases tolerated the treatment well. Evaluation of clinical improvement based on photographic assessment showed that at one month after the last laser treatment five of the ten patients (50%) demonstrated grade 1 clinical improvement, four (40%) showed grade 2 clinical

improvement and one (10%) grade 3 improvement. The clinical results at 6 months after the treatment revealed that seven patients (70%) had grade 4 clinical improvement (Figures 1 and 2) and three patients (30%) had grade 3 improvement. The mean clinical improvement score was 1.6 ± 0.70 at 1 month after the last treatment. At 3 months further improvement was noted with a mean of 2.5 ± 0.71 . By 6 months, the mean clinical improvement score was increased to 3.7 ± 0.48 (Figure 3 and 4). The clinical improve-

Figure 1 A 37-year-old Thai female with periorbital syringoma before the treatment (A) and 1 month after 3 sessions of fractional Erbium YAG 2,940 nm device; clinical improvement grade 2 (B) and 6 months after the treatment; clinical improvement grade 4 (C)

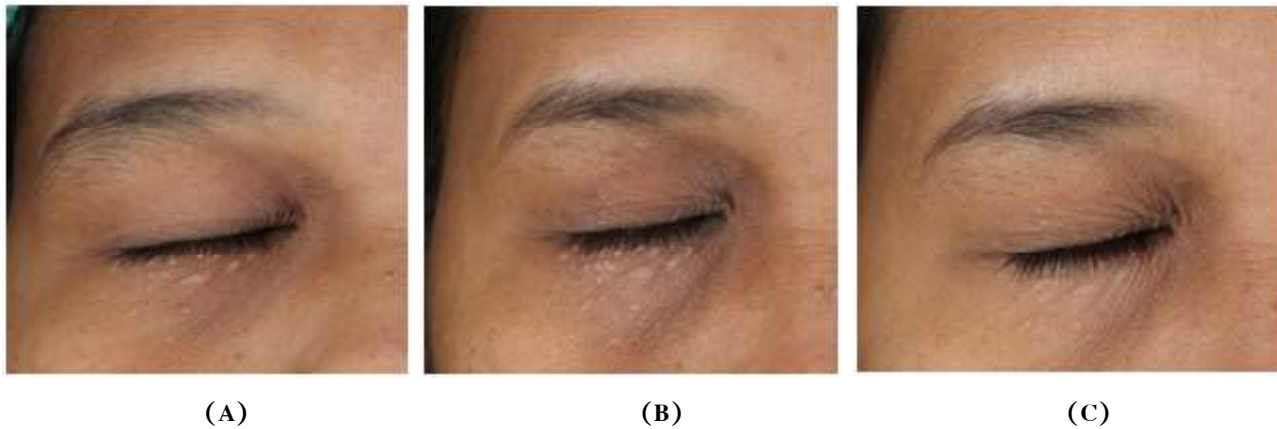

Figure 2 A 58-year-old Thai woman with periorbital syringoma before the treatment (A) and 1 month after the treatment; clinical improvement grade 3 (B) and 6 months after the treatment; clinical improvement grade 4 (C)



ment score at 1, 3 and 6 months after the last laser treatment were significantly different ($p < 0.05$). Furthermore, seven patients (70%) noticed the marked improvement in their periorbital wrinkles and skin texture.

Surveys for overall patient satisfaction at one month after treatment showed that five of the ten patients (50%) were slightly satisfied, two (20%) were very

satisfied, two (20%) was satisfied and one (10%) was unsatisfied. However at six months after the treatment, five out of ten patients (50%) were satisfied and four (40%) were very satisfied. There was only one patient who rated her satisfaction as unsatisfied (Figure 5). The overall satisfaction levels at 1, 3 and 6 months after the treatment were not significantly different (Figure 6).

Figure 3 Percentage of improvement vs. time. Results were graded by 2 dermatologists blinded to the treatment. The clinical improvement was evaluated based on pre- and post- photographs which were taken at baseline, 1, 3 and 6 months after the last laser treatment.

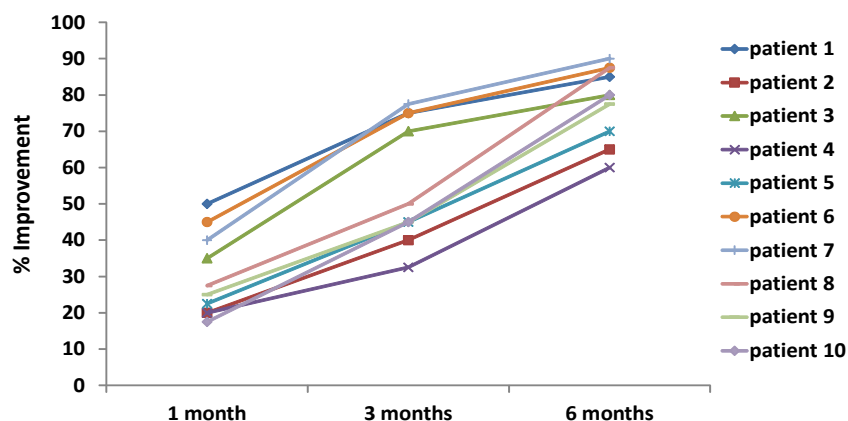


Figure 4 Grades of clinical improvement at 1, 3 and 6 months after 3 sessions of fractional Erbium YAG laser treatment compared with the baseline. At 6 months after the last laser treatment 70% of all patients had grade 4 clinical improvement and 30% of all patients had grade 3 improvement. The mean clinical improvement scores were 1.6, 2.5 and 3.7 at 1, 3 and 6 months respectively.

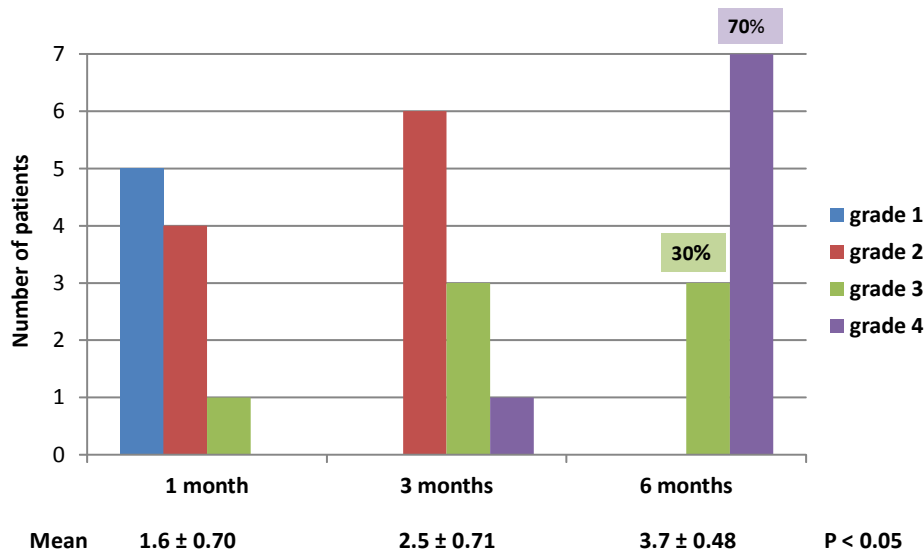


Figure 5 A 40-year-old Thai woman with periorbital syringoma before the treatment (A) and 1 month after the treatment; clinical improvement grade 2 (B) and 6 months after the treatment; clinical improvement grade 4 (C)

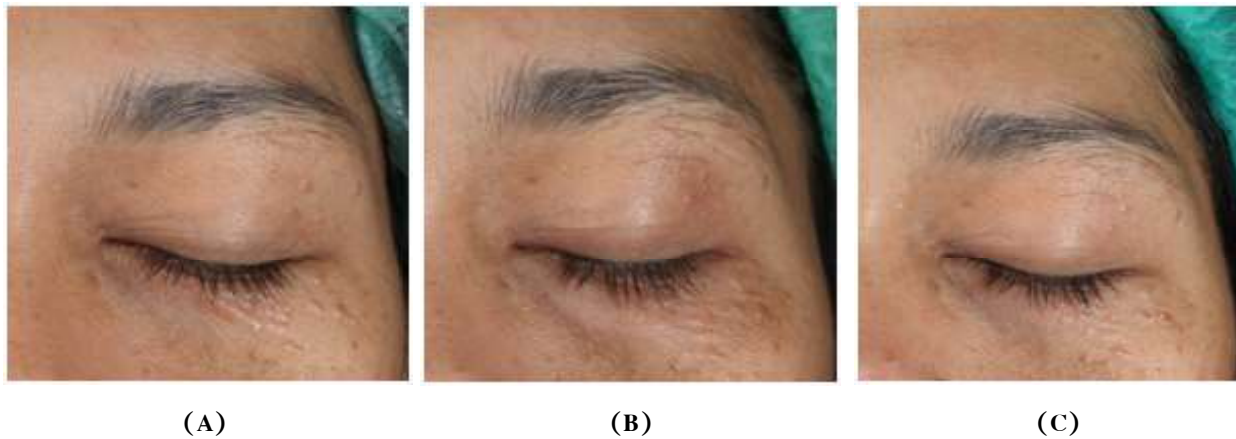
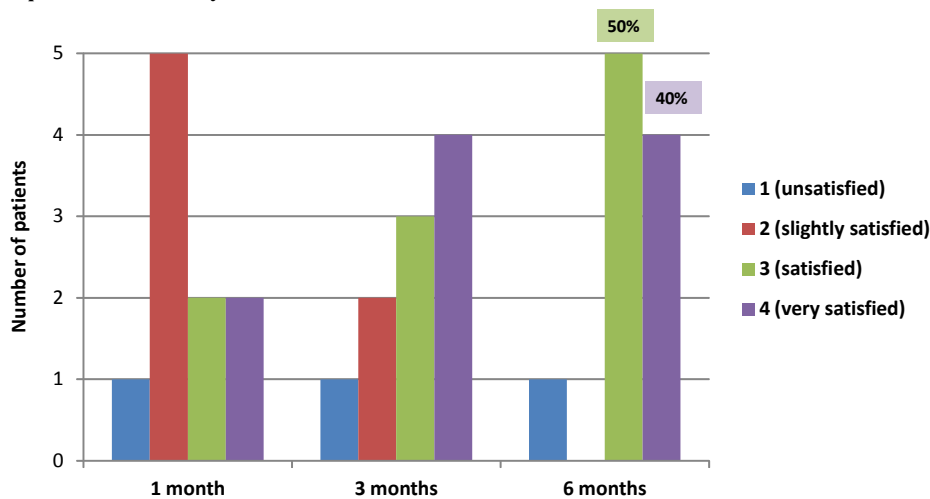


Figure 6 Patient satisfaction levels at 1, 3 and 6 months after 3 sessions of fractional Erbium YAG laser treatment compared with the baseline. At 6 months after the last laser treatment 50% of all patients were satisfied and 40% of all patients were very satisfied.



Four patients (40%) had post inflammatory hyperpigmentation which however completely resolved within 2 months after nightly application with 3% hydroquinone cream. No complications, such as infection, scarring, erythema, and pigmentary changes, were observed.

Discussion

Syringomas are common eccrine ductal adnexal tumors. Although they are benign and harmless, they

can cause significant cosmetic concern among affected individuals. An ideal treatment of syringomas is to selectively destroy the tumors with little damage to the normal tissue. The treatment should penetrate deep enough to cause total destruction to the base of the lesion and limiting regrowth, but total energy required to obtain this depth poses a risk of side effects. The average syringoma lesion depth determined in the previous study which reviewed 80 skin biopsy specimens was 0.70 ± 0.20 mm (range 0.4-1.2mm).⁽⁶⁾

In this study, we used 3 sessions of fractional Erbium YAG 2,940 nm laser with adjustable depths and coagulation setting to treat periorbital syringomas at 6 week interval. We found that this treatment was an effective and safe method for syringoma. All patients in our study had demonstrated significantly favorable clinical outcomes with mild complications or side effects. Because the treatment partially destroys the syringoma lesions, repeated treatment is required for complete removal. We used 3 sessions of fractional Erbium YAG laser to clear the small lesions and flatten the plaque type lesions. Therefore, additional sessions may be required to remove the larger lesions. However, from our study, three sessions of fractional Erbium YAG laser had resulted in grade 3 or grade 4 clinical improvement in all patients and remarkable patient satisfaction rate.

Cho, et al. also reported to obtain successful results with 2 sessions of ablative 10,600-nm carbon dioxide fractional laser at 1 month interval for the treatment of periorbital syringomas in 35 patients. However, the clinical improvement score at 2 and 4 months after the last fractional CO₂ treatment were not significantly difference.⁽¹⁾ Similar to the CO₂ fractional laser, the Erbium YAG laser is also highly absorbed by water, which acts as a chromophore in the tissue. The Erbium YAG laser operates at a wavelength of 2,940 nm, a value much closer to the 3,000 nm absorption peak of water and 3,030 nm absorption peak of collagen when compared to the CO₂ laser, which operates at a wavelength of 10,600 nm. Therefore the Erbium YAG laser is 12–18 times more absorbed by cutaneous tissue compared to the CO₂ laser, and it more selectively targets the superficial water-abundant epidermal and dermal layers.^(10,11)

The fractional Erbium YAG laser can also induce collagen remodeling which results in improvement of dermal thickness and rhytides. As seen in our study that the clinical improvement score was significantly increased at 1, 3 and 6 months respectively. Furthermore, 6 months after the last laser treatment, 70% of all patients noticed the marked improvement in their periorbital wrinkles and skin texture.

In conclusion, the fractional Erbium YAG laser with adjustable depths and coagulation settings could potentially serve as a new alternative treatment modality for periorbital syringoma which provides outstanding clinical outcomes and high safety margins when using repeatedly.

References

1. Cho SB, Kim HJ, Noh S, Lee SJ, Kim YK, Lee JH. Treatment of syringoma using an ablative 10,600-nm carbon dioxide fractional laser: a prospective analysis of 35 patients. *Dermatol Surg* 2011;37:433–8.
2. Sajben FP, Ross EV. The use of the 1.0 mm handpiece in high energy, pulsed CO₂ laser destruction of facial adnexal tumors. *Dermatol Surg* 1999;25:41–4.
3. Wang JI, Roenigk HH Jr. Treatment of multiple facial syringomas with the carbon dioxide (CO₂) laser. *Dermatol Surg* 1999; 25: 136–9.
4. Frazier CC, Camacho AP, Cockerell CJ. The treatment of eruptive syringomas in an African American patient with a combination of trichloroacetic acid and CO₂ laser destruction. *Dermatol Surg* 2001;27:489–92.
5. Akita H, Takasu E, Washimi Y, Sugaya N, Nakazawa Y, Matsunaga K. Syringoma of the face treated with fractional photothermolysis. *J Cosmet Laser Ther* 2009; 11:216–9.
6. Kang WH, Kim NS, Kim YB, Shim WC. A new treatment for syringoma. Combination of carbon dioxide laser and trichloroacetic acid. *Dermatol Surg* 1998;24:1370–4.

7. Park HJ, Lim SH, Kang HA, Byun DG, Houh D. Temporary tattooing followed by Q-switched alexandrite laser for treatment of syringomas. *Dermatol Surg* 2001;27:28-30.
8. Park HJ, Lee DY, Lee JH, Yang JM, Lee ES, Kim WS. The treatment of syringomas by CO₂ laser using a multiple-drilling method. *Dermatol Surg* 2007;33:310-3.
9. Al Aradi IK. Periorbital syringoma: a pilot study of the efficacy of low-voltage electrocoagulation. *Dermatol Surg* 2006;32:1244-50.
10. Kist DA, Elm CM, Eleftheriou LI, Studer JA, Wallander ID, Walgrace SE, Zelickson BD. Histologic analysis of a 2,940 nm fractional device. *Lasers Surg Med* 2011;43:79-91.
11. Weiss RA, Harrington AC, Pfau RC, Weiss MA, Marwaha S. Periorbital skin resurfacing using high energy erbium:YAG laser: results in 50 patients. *Lasers Surg Med*. 1999;24:81-6.

Abstract: ผลการรักษา Periorbital Syringomas โดยใช้ Fractional Erbium YAG Laser

จิโรจ ลินธวานนท์ พ.บ.; นัทยา วรวิฑูรินันท์ พ.บ.; จันทราภา จันทรางศุ พ.บ.ม., M.Sc.

สถาบันโรคผิวหนัง กรมการแพทย์ กระทรวงสาธารณสุข

วารสารวิชาการสาธารณสุข 2558;24:360-6.

Syringoma เป็นเนื้องอกชนิดไม่ร้ายแรงชนิดหนึ่งของผิวหนังที่พบบ่อยบริเวณรอบดวงตาซึ่งสามารถก่อปัญหาด้านความสวยงามสำหรับผู้ที่เป็นได้ การรักษา syringoma คือการทำลายส่วนเนื้องอกโดยให้ผลทำลายเนื้อเยื่อส่วนที่ปกติให้น้อยที่สุด ซึ่งในทางปฏิบัติเป็นไปได้เลยเมื่อใช้วิธีการรักษาแบบเดิม การใช้ fractional erbium YAG laser ในการรักษา periorbital syringoma ในการศึกษาครั้งนี้เพื่อศึกษาถึงประสิทธิผลและความปลอดภัยในการรักษาโดยเครื่องดังกล่าวสามารถปรับระดับความลึกของพลังงานและระยะความกว้างในการผิวกัดเส้นเลือดและการทำลายเนื้อเยื่อใกล้เคียง ผลการศึกษาผู้ป่วย 10 รายที่ทำการตรวจทางพยาธิวิทยา ยืนยันว่าเป็น periorbital syringoma โดยให้การรักษาด้วย fractional erbium YAG laser 3 ครั้งห่างกันทุก 6 สัปดาห์และมีการประเมินทางคลินิกจากภาพถ่ายผู้ป่วยเปรียบเทียบกับก่อนการรักษาและเมื่อ 1, 3 และ 6 เดือนหลังการรักษาด้วย laser ครั้งสุดท้าย ได้ผลการรักษาระดับ 4 ใน 7 รายและระดับ 3 ใน 3 ราย และมี clinical improvement score ที่ 1, 3 และ 6 เดือนแตกต่างกันอย่างมีนัยสำคัญทางสถิติ ($p < 0.05$) และจากการประเมินผลการรักษาโดยผู้ป่วยให้ผลเป็นพอใจมาก 4 ใน 10 ราย และพอใจ 5 ใน 10 ราย เมื่อประเมินที่ 6 เดือนหลังการรักษาครั้งสุดท้าย ไม่พบผลแทรกซ้อนใดๆ จากการรักษา ดังนั้น fractional erbium YAG laser จึงอาจเป็นทางเลือกในการรักษา periorbital syringoma โดยการทำให้หลายครั้ง ซึ่งให้ผลดี ไม่มีผลแทรกซ้อนใดๆ

คำสำคัญ: การใช้ fractional laser, การรักษาด้วย Erbium YAG laser, เนื้องอก periorbital syringomas