

Original Article

นิพนธ์ต้นฉบับ

Discoid Lateral Meniscus: The Cadaveric and Arthroscopic Studies

Pariyut Chiarapattanakom*

Krairoek Waiwatana**

Charoenchai Pakpianpairoj*

Prasert Liupolvanish*

*Center for Excellence in Orthopaedics, Lerdsin General Hospital, Bangkok, Thailand

**Department of Orthopaedic, Nan General Hospital, Nan, Thailand.

Abstract

Discoid lateral meniscus was reported to have a higher prevalence among Asian, especially in Japanese. To date, no cadaveric study of the discoid lateral meniscus in Thai population has been reported. This study intended to find the prevalence of discoid lateral meniscus from both cadaveric and arthroscopic findings.

Firstly, 259 embalmed knees were dissected. The discoid lateral menisci were identified and classified into 3 types according to Watanabe classification. Secondly, 719 records of arthroscopic procedures for internal derangement of the knee performed between 1995 and 2000 were reviewed. The age, gender, presenting symptoms and arthroscopic findings of the discoid lateral meniscus cases were recorded.

Of 259 embalmed dissected knees, there were 11 discoid lateral menisci (4.3%). Ten of this was incomplete type. Only one knee had complete type of discoid lateral meniscus. No Wrisberg ligament type was found. Of the total 719 knees underwent arthroscopic procedures, there were 62 knees of torn lateral menisci of all kinds (8.6%). Torn discoid lateral meniscus was found in 12 knees of these 62 torn lateral menisci group (1.7% of arthroscopic cases). There were 8 incomplete and 4 complete type.

The prevalence of the discoid lateral meniscus in this cadaveric study was not higher than the prevalence in previous studies in Caucasians. Although the prevalence of the discoid lateral meniscus in this cadaveric study was low, the ratio of the torn discoid lateral meniscus to the isolated tear of the normal lateral meniscus in our arthroscopic findings was as high as 1: 5. In conclusion, the discoid lateral meniscus was a common predisposing factor of a torn lateral meniscus.

Key words: discoid lateral meniscus, meniscus injury, meniscus variation

Introduction

Discoid lateral meniscus is a variation of the meniscus. It is different from normal meniscus in many

aspects: shape, thickness, mobility, composition, and probably susceptibility to injury⁽¹⁻³⁾. Tear through a discoid lateral meniscus is an indication for surgery

and should be considered as a differential diagnosis in a case of internal derangement of the knee. The most common symptoms are pain, knee clunk on flexion, and decreased range of motion⁽⁴⁻⁷⁾. The prevalence of the discoid lateral meniscus varies among studies^(1, 8-14). The controversies arise from different sources of data collection, surgical or cadaveric studies. It is difficult to compare prevalences from different kind of studies because the data from either source might have different implication to clinical uses. The purpose was to study the prevalence of the discoid lateral meniscus from cadaveric specimens and from arthroscopic findings in clinical cases.

Methodology

Prospective descriptive and retrospective descriptive study were done. Two hundred and fifty-nine embalmed knees were dissected in an anatomical laboratory between 1992 and 2000. There were 95 males and 45 females. The age ranged from 18 to 97 years old, average 71 years old. The quadriceps tendon was cut 2 inches above the patella. The incision was carried down both medially and laterally so that the patella could be reflected inferiorly, permitting the knee to be flexed to 90 degrees. (Figure 1) According to Watanabe classification⁽¹⁵⁾, there are three types of discoid meniscus: complete, incomplete, and Wrisberg ligament type. The meniscus was defined as incomplete discoid if the width of meniscus was over 50 percent but less than 100 percent of the tibial plateau width. The complete type of discoid lateral meniscus was defined as a meniscus that covered the entire tibial plateau. Both the incomplete and complete type have normal meniscal attachment. Wrisberg ligament type of meniscus was defined as a meniscus which may be full discoid or fairly normal has no posterior capsular attachment except the ligament of Wrisberg.

Seven hundred and nineteen records of arthroscopic procedures for internal derangement of

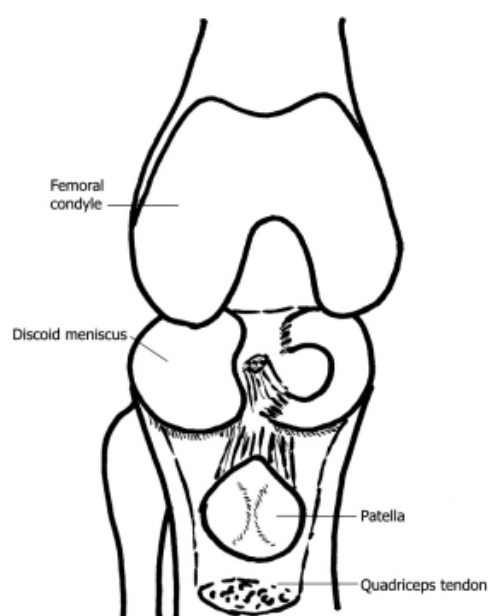


Fig. 1 The quadriceps tendon was cut and reflected downward. The lateral meniscus covered the entire lateral tibial plateau and was classified as complete type of discoid lateral meniscus.

the knee performed between 1995 and 2000 were also reviewed. The number of surgery which involved only meniscus was recorded. The age, gender, presenting symptoms and type of the torn discoid lateral menisci were noted. Descriptive statistics were employed in data analysis.

Results

Eleven of 259 knees dissected had discoid lateral meniscus. There were 10 incomplete and 1 complete discoid lateral menisci. All of these menisci securely attached to the tibia by meniscotibial ligament. No Wrisberg ligament type was found. Among the knees with discoid lateral meniscus, 4 knees in 2 cases were bilateral, the rest were unilateral. The posterior menisiofemoral ligament was found connecting the posterior horn of the lateral discoid meniscus to the medial femoral condyle in 7 of 11 knees. In one knee, both anterior and posterior menisiofemoral ligaments connected the posterior horn to the medial femoral condyle. Three knees with discoid lateral meniscus

had neither attachment to anterior or posterior meniscomfemoral ligament. All of the discoid lateral menisci found in this study attached to the tibia by coronary ligament. Except for the minor fraying of the edge of the discoid lateral meniscus, any gross pathology of any of the discoid lateral menisci could not be demonstrated.

Of the 719 arthroscopic procedures, there were 12 knees with torn discoid lateral meniscus. The age ranged from 12-57 (average 30) years old. There were 6 males and 5 females. Pain was the common presenting symptom in all cases. There were 12 torn discoid lateral meniscus; 8 incomplete and 4 complete type. No Wrisberg ligament type was found. Partial meniscectomy was done in all cases. Other than torn discoid lateral menisci, there were 50 knees of isolated lateral meniscus tear and there were 36 knees of isolated medial meniscus tear in this study.

Discussion

A normal lateral meniscus covers approximately 20 percent of lateral tibial plateau surface and forms a congruent surface for the lateral femoral condyle. It is shaped like the letter 'c' and is larger and thicker than a normal medial meniscus. The most common variation of the meniscus is a disc-shaped or so-called discoid meniscus. A discoid meniscus is much thicker than a normal meniscus. The maximum thickness ranged from 4 to 13.5 mm¹.

The etiology of the discoid lateral meniscus is unknown. Smillie⁽²⁾ hypothesized that this type of meniscus was a failure of the normal meniscus to undergo absorption of the central portion during development. However, Kaplan⁽⁵⁾ and Clark and Ogden⁽¹⁶⁾ did not find a disc-shaped meniscus at any stage of human fetus. All the patients observed at operations in Kaplan study⁽⁵⁾, the discoid lateral meniscus had no posterior attachment to the tibia. The meniscus was attached to the femur by Wrisberg ligament. This

variation allows for more movement of the posterolateral portion of meniscus during flexion and extension of the knee. He proposed that this increased abnormal movement led to development of hypertrophied disc-shaped meniscus⁽⁵⁾. In our study, not all of the knees with discoid lateral meniscus attached to the posterior meniscomfemoral or Wrisberg ligament, and that all meniscus attached to the tibia by coronary ligament, therefore Kaplan's theory might not be applicable to explain our results.

The average age of cadaver with discoid lateral meniscus in our study is 71 years old. All of the discoid meniscus had no tears except for minor edge fraying. Though, discoid lateral meniscus could be observed in patients of all ages^(11,17,18), symptomatic discoid menisci were thought to occur almost exclusively in children and young adults^(8,9,11,13,18-23). Even though the history of the knee symptoms of cadaver during the lifetime of each subject could not be traced back, the discoid meniscus could be found in old age group without any gross pathology to the meniscus in this series.

The prevalence of this type of meniscus varies from 0.89 to 32 percent^(1,8-14). The prevalence was assumed to be related to ethnic group and was higher in Asians^(8,12). At a closer look to these studies, there were clinical studies which were performed in group of patients undergoing arthroscopic procedures and those studies from cadaveric specimens in the laboratory. Anatomical studies for the discoid lateral meniscus were done in 301 cadavers by Kato et al.⁽⁸⁾, 300 cadavers by Casscells⁽¹⁰⁾ and in 200 cadavers by Noble⁽¹⁴⁾. The prevalences of the discoid lateral meniscus found to be 32, 5 and 7 percent respectively. To the best of our knowledge, this study is the first report of prevalence of the discoid lateral meniscus in anatomical specimens in Thais which are Asian population. There were 11 discoid lateral meniscus in 259 knees studied. The prevalence is 4.25 percent and re-

portedly. This percentage age is comparable to the study done in Caucasians.

Clinical studies which were done in Korea and Japan showed the prevalence were as high as 14 - 32 percent^(1,8,13). In these studies, the discoid menisci were observed from cases that underwent various arthroscopic procedures. Compare to similar clinical studies in Caucasians, which the prevalence of discoid lateral meniscus of the arthroscopic cases ranged from 0.9 to 5.2 percent⁽⁸⁻¹¹⁾, the prevalences of discoid lateral meniscus that needed surgery seemed to be higher among Asians. Of the 719 arthroscopic procedures for internal derangement of the knees in this study, there were 12 knees with torn discoid lateral meniscus accounting for the prevalence of tear of this type of meniscus of 1.7 percent. The prevalence of our study in Thai population is not so high as in Korean or Japanese^(1,8,13). From anthropological standpoint, Thai is Southern Mongoloid whereas Japanese and Korean are Classical Mongoloid. It is still questionable whether races had an influence on the prevalence of this problem.

Of the 62 surgeries for the lateral meniscus, the ratio of the tear discoid lateral meniscus to the isolated tear of the normal lateral meniscus was as high as 12:62. In the other words, approximately 1: 5 of the torn lateral meniscus which needed surgery was discoid in appearance. This ratio exceeded the prevalence of the discoid lateral meniscus found in our cadaveric study. The abnormal anatomy of the discoid meniscus might have a deleterious effect to the meniscus and cause the meniscus to be easily injured.

Contrary to previous beliefs, the prevalence of the discoid lateral meniscus in this study is not higher than the prevalence in Caucasians. Concerning the tear of the lateral meniscus, the proportion of the torn discoid lateral meniscus was high. These findings suggest that the discoid lateral meniscus is more susceptible to injury than normal shape lateral meniscus.

References

1. Ikeuchi H. Arthroscopic treatment of the discoid lateral meniscus. Technique and long-term results. *Clin Orthop* 1982; 167:19-28.
2. Smillie IS. The congenital discoid meniscus. *J Bone Joint Surg* 1948; 30 B: 671-82.
3. Woods GW, Whelan JM. Discoid meniscus. *Clin Sports Med* 1990; 9:695-706.
4. Aichroth PM, Patel DV, Marx CL. Congenital discoid lateral meniscus in children. A follow-up study and evaluation of management. *J Bone Joint Surg* 1991; 73B: 932-6.
5. Kaplan EB. Discoid lateral meniscus of the knee joint. *J Bone Joint Surg* 1957; 39A: 77-87.
6. Pellacci F, Montanari G, Prosperi P, Galli G, Celli V. Lateral discoid meniscus: treatment and results. *Arthroscopy* 1992; 8:526-30.
7. Raber DA, Friederich NF, Hefti F. Discoid lateral meniscus in children. Long-term follow-up after total menisectomy. *J Bone Joint Surg* 1998; 80A: 1579-86.
8. Kato Y, Oshida M, Aizawa S, Saito A, Ryu J. Discoid lateral menisci in Japanese cadaver knees. *Mod Rheumatol* 2004; 14:154-9.
9. Cave EF, Staples OS. Congenital discoid meniscus. A cause of internal derangement of the knee. *Am J Surg* 1941; 54:371-6.
10. Casscells SW. Gross pathological changes in the knee joint of the aged individual. A study of 300 cases. *Clin Orthop* 1978; 132:225-32.
11. Dickhaut SC, DeLee JC. The discoid lateral-meniscus syndrome. *J Bone Joint Surg* 1982; 64A: 1068-73.
12. Fritschy D, Gonseth D. Discoid lateral meniscus. *Int Orthop* 1991; 15:145-7.
13. Kim SJ, Kim DW, Min BH. Discoid lateral meniscus associated with anomalous insertion of the medial meniscus. *Clin Orthop* 1995; 315:234-7.
14. Noble J. Lesion of the menisci. *J Bone Joint Surg* 1977; 59A: 480-3.
15. Watanabe M, Takeda S, Ikeuchi H. Atlas of arthroscopy. 3rd ed. Tokyo: Igaku Shoin; 1978.
16. Clark CR, Ogden JA. Development of the menisci of the human knee joint. *J Bone Joint Surg* 1983; 65A: 538-47.
17. Berson BL, Hermann G. Torn discoid menisci of the knee in adults: Four cases reports. *J Bone Joint Surg* 1979; 61A: 303.
18. Jeannopoulos CL. Observations of discoid meniscus. *J Bone Joint Surg* 1950; 32A: 649-52.
19. Barnes CL, McCarthy RE, Van der Schilden JL,

- McConnell JR, Nusbickel FR. Discoid lateral meniscus in a young child: case report and review of the literature. J Pediatr Orthop 1988; 8:707-9.
20. Ellis VH, Camb BC. Congenital abnormality of the external semilunar cartilage. Lancet 1932; 1: 1359.
21. Hayashi LK, Yamaga H, Ida K, Miura T. Arthroscopic meniscectomy for discoid lateral meniscus in children. J Bone Joint Surg 1988; 70 A: 1495-500.
22. Middleton DS. Congenital disc-shaped lateral meniscus with snapping knee. Brit J Surg 1936; 24:246-55.
23. Nathan PA, Cole SC. Discoid meniscus. A clinical and pathologic study. Clin Orthop 1969; 64:107-13.

บทคัดย่อ หมอนรองข้อเข่าแบบดิสคอยด์: การศึกษาจากศพและการส่องกล้องข้อเข่า
ปริญญ์ เจริญพัฒนามคม*, ไกรฤกษ์ วัชวัฒนะ**, เจริญชัย พากเพียรไพโรจน์*, ประเสริฐ หลิวผลวนิช*
*ศูนย์การแพทย์เฉพาะทางด้านออร์โธปิดิกส์ โรงพยาบาลเลิดสิน กรมการแพทย์ กระทรวงสาธารณสุข
**โรงพยาบาลน่าน สำนักงานปลัดกระทรวง กระทรวงสาธารณสุข
วารสารวิชาการสาธารณสุข 2551; 17:SVI1589-93.

มีรายงานพบหมอนรองข้อเข่าแบบดิสคอยด์ได้บ่อยในชาวเอเชีย โดยเฉพาะชาวญี่ปุ่น การศึกษานี้มีวัตถุประสงค์เพื่อศึกษาความชุกของหมอนรองข้อเข่าแบบดิสคอยด์จากการศึกษาในศพและการส่องกล้องข้อเข่า

ผู้ศึกษาได้ศึกษาความชุกของหมอนรองข้อเข่าแบบดิสคอยด์ โดยการชำแหละเข่าจากศพดองจำนวน 259 เข่า และจากบันทึกผู้ป่วยที่เข้ารับการรักษาผ่าตัดส่องกล้องเนื่องจากมีปัญหาลำบากในเข่าแบบต่าง ๆ จำนวน 719 เข่า ผู้ป่วย ได้รับการบันทึกอายุ เพศ อาการที่มาพบแพทย์ และสิ่งที่พบในขณะที่ส่องกล้องตรวจเข่า

จากการศึกษาในศพ พบหมอนรองข้อเข่ารูปดิสคอยด์จำนวน 11 เข่า (4.3%) เป็นหมอนรองข้อเข่ารูปดิสคอยด์แบบไม่สมบูรณ์ 10 เข่า แบบสมบูรณ์ 1 เข่า ไม่พบหมอนรองข้อเข่าแบบที่ต่อเนื่องกับเอ็นริสเบอร์กเลย เข่าซึ่งได้รับการส่องกล้องทั้งสิ้น 719 เข่า พบหมอนรองข้อเข่าใกล้ริมขาด 62 เข่า (8.6%) ในจำนวนนี้เป็นหมอนรองข้อเข่ารูปดิสคอยด์ 12 เข่า (1.7% ของเข่าที่ได้รับการส่องกล้อง) พบหมอนรองข้อเข่ารูปดิสคอยด์ชนิดไม่สมบูรณ์ 8 เข่า ชนิดสมบูรณ์ 4 เข่า

ความชุกของการพบหมอนรองข้อเข่ารูปดิสคอยด์ในศพไม่สูงกว่าที่เคยมีการศึกษาในคนมีชีวิต ถึงแม้ว่าความชุกของการพบหมอนรองข้อเข่ารูปดิสคอยด์จากการศึกษาในศพจะไม่สูง แต่หมอนรองข้อเข่าที่แตกมีสัดส่วนของหมอนรองข้อเข่ารูปดิสคอยด์สูงถึง 1:5 จากสัดส่วนดังกล่าวนี้ ทำให้อนุมานได้ว่า หมอนรองข้อเข่ารูปดิสคอยด์น่าจะเป็นเหตุที่ทำให้หมอนรองข้อเข่าฉีกขาดได้ง่าย

คำสำคัญ: หมอนรองข้อเข่าแบบดิสคอยด์, หมอนรองข้อเข่าฉีก, ความผันแปรของหมอนรองข้อเข่า