

การกดทับแขนงหลังของเส้นประสาท mandibular โดยกล้ามเนื้อ lateral pterygoid

พรทิพย์ บุญเรืองศรี, โกวิท ไชยศิวิมมงคล, สิทธิชัย เอี่ยมสะอาด, สุภัจฉรี อรัญ*

ภาควิชากายวิภาคศาสตร์ คณะแพทยศาสตร์ มหาวิทยาลัยขอนแก่น

Entrapment of Posterior Divisions of the Mandibular Nerve by the Lateral Pterygoid Muscle

Porntip Boonruangsri, Kowit Chaisiwamongkol, Sitthichai Iamsaard, Supatcharee Arun*

Department of Anatomy, Faculty of Medicine, KhonKaen University, Thailand, 40002

หลักการและวัตถุประสงค์: เส้นประสาท mandibular เป็นแขนงสำคัญที่เลี้ยงบริเวณใต้ต่อขมับและภายในช่องปาก ในทางคลินิกการกดทับเส้นประสาทนี้จะทำให้เกิดอาการชาหรือเจ็บปวดหรือเป็นทั้งสองอย่างในบริเวณที่เส้นประสาทกระจายไปเลี้ยง บางครั้งก็เกิดอาการเจ็บปวดเวลาพูด วัตถุประสงค์ของการศึกษานี้เพื่อศึกษาการกดทับของเส้นประสาท mandibular แขนงหลังโดยกล้ามเนื้อ lateral pterygoid ในศพของคนไทย

วิธีการศึกษา: ศีรษะผ่าครึ่งซีกจำนวน 100 ข้างในศพของคนไทย นำมาผ่าศึกษาและสังเกตการกดทับของเส้นประสาท mandibular แขนงหลังโดยผิวในของกล้ามเนื้อ lateral pterygoid บันทึกข้อมูลในแบบเก็บข้อมูล

ผลการศึกษา: พบแบบผิดปกติที่มีการกดทับของเส้นประสาท mandibular แขนงหลังโดยหัวบนของกล้ามเนื้อ lateral pterygoid จำนวนร้อยละ 9 (9 ข้าง เป็นเพศชาย 7 และหญิง 2 ข้าง) ส่วนแบบปกติที่ไม่มีการกดทับเส้นประสาทโดยหัวบนหรือหัวล่างของกล้ามเนื้อ lateral pterygoid จำนวนร้อยละ 91 (91 ข้าง เป็นเพศชาย 45 และหญิง 46 ข้าง)

สรุป: การพบการกดทับของเส้นประสาท mandibular แขนงหลังโดยหัวบนของกล้ามเนื้อ lateral pterygoid ในศพของคนไทยจำนวนถึงร้อยละ 9 เป็นข้อมูลที่ช่วยสนับสนุนทฤษฎีที่ว่าในบางกรณีที่มีการปวดข้อต่อ temporomandibular การปวดใบหน้าตลอดเวลาโดยไม่ทราบสาเหตุและอาการปวดของกล้ามเนื้อและเยื่อหุ้มบริเวณใบหน้า อาจมีสาเหตุจากเส้นประสาท mandibular แขนงหลังถูกกดทับในบริเวณแอ่งใต้ขมับ

คำสำคัญ: เส้นประสาท mandibular แขนงหลัง, การกดทับเส้นประสาท, กล้ามเนื้อ lateral pterygoid

Background and Objectives: The branches of the posterior division of the mandibular nerve (MNsP) are the important nerves which supply the infratemporal fossa and oral cavity. Clinically, the nerve entrapment by muscle leads to numbness, pain, or both symptoms in the respective area of nerve distribution. It could also be pain during speaking or oral movements. Therefore, this study aimed to investigate the variations of MNsP entrapment by lateral pterygoid muscle (LPM) in Thai embalmed cadavers.

Methods: One hundred hemi-sectioned heads of Thai embalmed cadavers were carefully dissected to observe MNsP distribution and the inner surface of the LPM. The patterns of nerve entrapments were recorded and photographed.

Results: The results showed that the MNsP variation (entrapment) type by LPM (superior head) was found as 9% (9 cases, males=7, females=2). In the rest 91 cases (91%; 91 cases, males=45 and females=46), the patterns of MNsP were found to be normal type and they were not entrapped by superior or inferior head of LPM.

Conclusions: The incidence of MNsP entrapment by superior head of LPM in Thai embalmed cadavers was approximately 9%. This information may support the theory that some cases such as temporomandibular joint syndrome, persistent idiopathic facial pain, and myofascial pain syndrome may result from entrapment neuropathies of MNsP in the infratemporal fossa.

*Corresponding author : Supatcharee Arun, Department of Anatomy, Faculty of Medicine, KhonKaen University, Thailand, 40002 Email: supatar@kku.ac.th

Keywords: Branches of the posterior division of the mandibular nerve, Nerve entrapment, Lateral pterygoid muscle

ศรีนครินทร์เวชสาร 2562; 34(4): 327-327. • Srinagarind Med J 2019; 34(4): 324-327.

Introduction

The branches of the posterior division of the mandibular nerve (MNsP) are important nerves supplying the structures in the infratemporal fossa (ITF) and oral cavity. The posterior trunk of the mandibular division of the trigeminal nerve normally descends deeply to the lateral pterygoid muscle (LPM)¹. Recently, it is believed that some cases of temporomandibular joint syndrome (TMJS), persistent idiopathic facial pain (PIFP) and myofascial pain syndrome (MPS) may be caused from entrapment neuropathies of the mandibular nerve (MN) in the ITF¹. Clinically, the entrapment of such nerves by muscle leads to numbness, pain, or both symptoms in the respective area of nerve distribution. It could also feel pain during speaking². The orofacial manifestations of myofascial pain are prevalent and most often results from entrapment of branches of trigeminal nerve. Entrapment of the nerve can occur from tightness of the lateral pterygoid muscle secondary to temporomandibular joint dysfunction³. Furthermore, the nerve entrapments and nerve communications are associated with symptoms of temporomandibular joint disorder and with possible collateral route of motor innervation to facial expression muscles respectively⁴. The investigations of MNsP entrapment by superior or inferior head of LPM, or pterygospinous ligament have been reported in many races¹⁻⁹. There was a case report from the patient presented with referring tingling in the left hemifacial region and ipsilateral lingual side for one year with discomfort when shaving or skin compression⁵. It had a few reports from Thai population. However, the variation of MNsP entrapment in Thais has never been reported. Therefore, this study attempted to investigate the MNsP entrapment by LPM in Thai embalmed cadavers.

Materials and Methods

One hundred hemi-sectioned heads of Thai embalmed cadavers (range of age = 74-56 years, 52 males and 48 females) were used to be observed. The domicile cadavers used to live in the Northeastern

region of Thailand and perfused with formaldehyde standard fixative.

In all specimens, the heads were opened by using a high-speed electric drill and a range our at the midsagittal line. The specimens were dissected out from the medial to lateral aspect. The medial pterygoid muscle (MPt.) was reflected to identify the MNsP distribution. The specimens were observed for the MNsP entrapment by the inner surface of the LPM (both superior and inferior heads). The variant specimens were photographed and recorded into the recorded forms. The investigations were performed in Gross Anatomy laboratory room, Department of Anatomy, Faculty of Medicine, Khon Kean University.

Data Analyses

The patterns of MNsP were classified into two types; normal and variation types. The MNsP variation type was entrapped by LPM (superior head) while the normal type has no nerve entrapment by LPM (superior head or inferior head) of each type was calculated as the percentage.

Results

The results showed that the MNsP variation (entrapment) type by superior head of LPM was found to be 9% (9 cases, males=7 and females=2). Such MNsP entrapment type was found at 1 right side and 6 left sides in males while observed at only 2 right sides in females (Table 1). In 91% (or 91 cases), they were classified as normal type which was no nerve entrapment by superior or inferior head of LPM. The MNsP normal type in males was 45% (right = 24% and left 21%) and this type in females was 46% (right = 23 % and left = 23%), respectively (Table 1). The incidence and representative figure of MNsPs were shown in Table 1 and Figures 1 and 2. Obviously, the normal type of MNsP was demonstrated in figure 1 while the variation type of mandibular nerve branch of posterior division was shown in figure 2.

Table 1 Incidence of the variant branches of the posterior division of the mandibular nerve (MNsP) observed in Thais

Types	Side numbers		Total (N=100)
	Right (N = 50)	Left (N = 50)	
MNsP variation (entrapment) type:			
- Male (mean age = 71.71 years)	1	6	7
- Female (mean age = 69 years)	2	Normal	2
MNsP normal type: (mean age = 74.56 years)			
- Male	24	21	45
- Female	23	23	46
Total	50	50	100

MNsP: Branches of the posterior division of the mandibular nerve

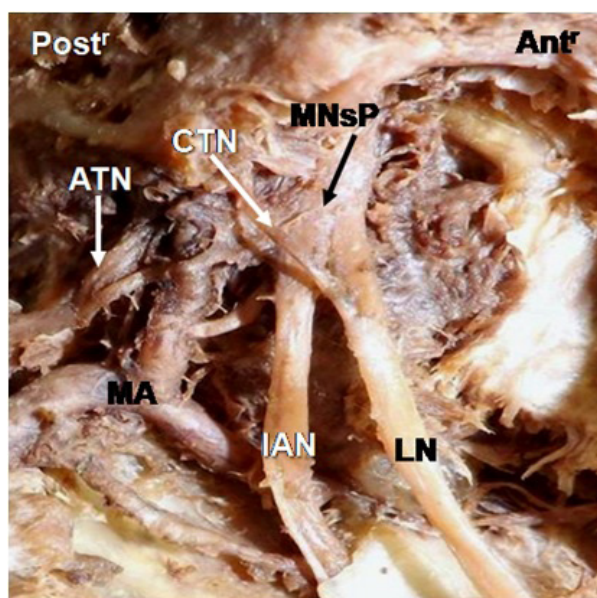


Figure 1 Showing normal type of mandibular nerve branch posterior division (MNsP) in left side of a hemi-section head. LN: Lingual nerve, IAN: Inferior alveolar nerve, ATN: Auriculotemporal nerve, CTN: Chorda tympani nerve, MA: Maxillary artery, Antr: Anterior view, Postr: Posterior view

Discussions

Previous studies have shown that the MNsP could be trapped by LPM pterygospinous ligament^{1,4,9}. In contrast to our investigation, the MNsP entrapment was found only by the superior head of LPM. Loughna and coworkers¹ reported that 3 of 52 Americans dissected (5.77%) showed three main branches of the posterior trunk of the mandibular nerve that pass through the medial fibers of the inferior head of the LPM. In recent study, the numbers

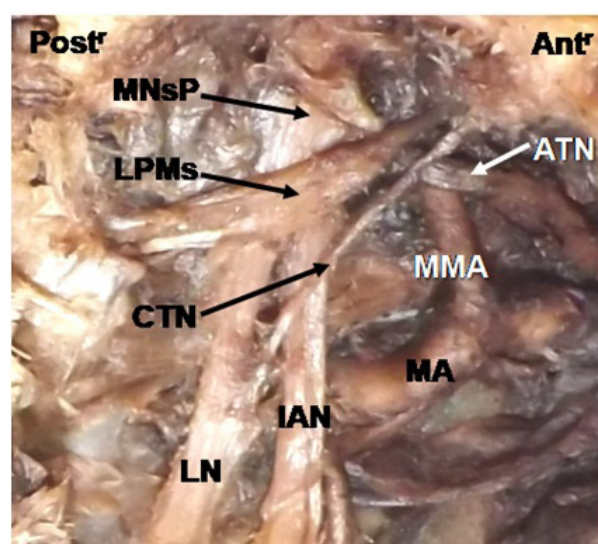


Figure 2 Showing the representative variation type of mandibular nerve branches posterior division (MNsP) in right side of hemi-section head. The MNsP was entrapped by the superior head of lateral pterygoid muscle (LPMs), LN: Lingual nerve, IAN: Inferior alveolar nerve, ATN: Auriculotemporal nerve, CTN: Chordatympani nerve, MA: Maxillary artery, MMA: Middle meningeal artery, Antr: Anterior view, Postr: Posterior view

of our specimens (100 sides) were greater than that of Loughna et al¹, which showed 9% of MNsP entrapment by superior head of LPM. In addition, Kang, et al⁴ reported the associations between temporomandibular disorder and anatomico-clinical relevance in 24 hemi-sectioned Korean heads by the topography of the nerve distribution on two heads of lateral pterygoid. Such reports demonstrated that incidences of the intramuscular nerve loop within the inferior head of LPM were 5 cases (20.83%). In

comparison to the nerve entrapment, the case numbers in Korean study were greater than those of Thai cadavers. The number of specimen in Kang, et al⁴ was lesser than our investigation which enhanced nerve entrapment in inferior head of LPM in the greater number than this study. Gonzales and Escoda 10% one case report of a 45-year-old man Spanish referring tingling in the left hemifacial region and ipsilateral lingual side for one year, with discomfort when shaving or skin compression. They showed several branches of the trigeminal nerve running through the masticatory muscles. This evidence suggested that there are mostly involved in the lingual and buccal nerves. The hyperactivity of the muscle bundles is crossed by nerve structures which generate a compression of the nerve. These events could be used to explain the certain orofacial neuropathies (numbness and/ or pain)¹⁰. Chronic nerve compression alters the normal anatomical and functional integrity of the nerve. The dentists and oral maxillofacial surgeons should be very suspicious for possible signs of neurovascular compression in the region of the ITF¹¹. Therefore, our study observed in Thai cadavers for MNsP entrapment by superior head of LPM can support the idea of entrapment neuropathies from mandibular nerve within the infratemporal fossa.

Conclusion

This study reported 9% of the MNsP entrapment by the superior head of LPM in Thai embalmed cadavers. Our findings were different from the previous reports because their results were MNsP entrapment by the inferior head or pterygospinous ligament. Therefore, this information may be used to explain some cases of temporomandibular joint syndrome, persistent idiopathic facial pain, and myofascial pain syndrome caused from the entrapment neuropathies of MNsP in the infratemporal fossa.

Acknowledgements

This study was supported by Invitation Research Fund (IN58129), the Faculty of Medicine Research Grant, Khon Kaen University, Thailand.

References

1. Loughna BA, Larkin LH, Marhan PE. Nerve entrapment in the lateral pterygoid muscle. *Oral Surg Oral Med Oral Pathol* 1990; 69: 299-360.
2. Piagkou M, Domestica T, Piagkos G, Ioannis C, Skandalakis P, Johnson EO. The Mandibular Nerve: The Anatomy of Nerve Injury and Entrapment. *Maxillofacial Surgery* 2012: 71-83.
3. Allum AES, Khalil AAF, Eltawab BA, Wu WD, Chang KV. Ultrasound-Guided Intervention for Treatment of Trigeminal Neuralgia: An updated Review of Anatomy and Techniques. *Research and Management* 2018: 1-6.
4. Kang HC, Kwak HH, Park HD, Kang MG, Kim HJ. Topographic Anatomy of the Mandibular Nerve Branches Distributed on the Lateral Pterygoid Muscle. *Korean J Phys Anthropol* 2002; 15: 79-93.
5. Piagkou M, Domestica T, Piagkos G, Giorgios A, Panagiotis S. Lingual Nerve Entrapment in Muscular and Osseous Structures. *Int J Oral Sci* 2010; 2: 181-9.
6. Piagkou M, Domestica T, Skandalakis P, Johnson EO. Functional Anatomy of the Mandibular Nerve: Consequences of Nerve Injury and Entrapment. *Clin Anat* 2011; 24: 143-50.
7. Peuker ET, Fischer G, Filler TJ. Entrapment of the Lingual Nerve Due to an Ossified Pterygospinous Ligament. *Clin Anat* 2001; 14: 282-4.
8. Kim SY, Hu KS, Chung IH, Lee EW, Kim HJ. Topographic anatomy of the lingual nerve and variations in communication pattern of the mandibular nerve branches. *Surg Radiol Anat* 2004; 26: 128-35.
9. Nayak SR, Rai R, Khrisnamurthy A, Prabhu LV, Ranade V, Mansur DI, et al. An usual course and entrapment of the lingual in the infratemporal fossa. *Bratisl Lek Listy* 2008; 109: 525-7.
10. Gonzalez JA, Escoda CG. Sensory disturbances of buccal and lingual nerve by muscle compression: A case report and review of the literature. *J Clin Exp Dent* 2016; 8: e93-6.
11. Piagkou M, Domestica T, Piagkos G, Ioannis C, Skandalakis P, Johnson E. The Mandibular Nerve: The Anatomy of Nerve Injury and Entrapment. *Maxillofacial Surgery*, Prof. Leon Assael (Ed); 2012: 83.