

ผลลัพธ์ของการผ่าตัดผ่านกล้องเพื่อเอาเนื้องอกมดลูกออก ในโรงพยาบาล ศรีนครินทร์

อมรรัตน์ เต็มธนะกิจไพศาล, ธีระยุทธ เต็มธนะกิจไพศาล

ภาควิชาสูติศาสตร์และนรีเวชวิทยา คณะแพทยศาสตร์ มหาวิทยาลัยขอนแก่น

Laparoscopic Myomectomy Outcomes: an Experience in Srinagarind Hospital

Amornrat Temtanakitpaisan , Teerayut Temtanakitpaisan

Department of Obstetrics and Gynecology, Faculty of Medicine, Khon Kaen University, Khon Kaen, Thailand

วัตถุประสงค์: เพื่อศึกษาผลลัพธ์จากการผ่าตัดผ่านกล้องเพื่อเอาเนื้องอกมดลูกออก ในช่วงระหว่างผ่าตัดและหลังผ่าตัด ในโรงพยาบาลศรีนครินทร์

วิธีการศึกษา: ทำการศึกษาย้อนหลังของการผ่าตัดผ่านกล้องเพื่อเอาเนื้องอกมดลูกออก จากข้อมูลการผ่าตัด และจากฐานข้อมูลของพยาธิวิทยา ระหว่างเดือน กรกฎาคม พ.ศ.2561 ถึง มิถุนายน พ.ศ.2562 จำนวน 11 รายที่ได้รับการผ่าตัดผ่านกล้องเพื่อเอาเนื้องอกมดลูกออกที่ใช้เทคนิคเหมือนกันในการผ่าตัด และนำเสนอข้อมูลพื้นฐานทั่วไป เช่น อายุ น้ำหนัก ส่วนสูง จำนวนการตั้งครรภ์ อาการที่เกิดจากเนื้องอกมดลูก การใช้ยาฉีดยา GnRH agonist ก่อนผ่าตัด ข้อมูลของเนื้องอกมดลูกขณะทำการผ่าตัด เช่น ชนิด จำนวน ขนาด ขนาดเนื้องอกที่ใหญ่ที่สุด และผลลัพธ์ขณะและหลังการผ่าตัด

ผลการศึกษา: ค่าเฉลี่ยอายุ และดัชนีมวลกายของคนไข้ที่ได้รับการผ่าตัดผ่านกล้องเพื่อเอาเนื้องอกมดลูกออก คือ 35.5 ปี และ 22.7 กิโลกรัม/ตารางเมตร ตามลำดับ ข้อบ่งชี้ที่ได้รับการผ่าตัดที่พบมากที่สุด คือ การที่มีเลือดประจำเดือนออกมากผิดปกติ และมีอาการปวดประจำเดือน/ปวดท้องน้อยร่วมด้วย การผ่าตัดผ่านกล้องเพื่อเอาเนื้องอกมดลูกออกสำเร็จ จำนวน 10 รายจากทั้งหมด 11 ราย (ร้อยละ 90.0) ค่าเฉลี่ยของปริมาณเลือดที่เสียไปจากการผ่าตัด และค่าเฉลี่ยของระยะเวลาการผ่าตัด คือ 320.0 มิลลิลิตร และ 155.4 นาที ตามลำดับ ค่ากลางของระยะเวลาที่ผู้ป่วยรักษาตัวในโรงพยาบาลหลังผ่าตัด คือ 3 วัน จากการศึกษาไม่พบภาวะแทรกซ้อนจากการผ่าตัด เช่น แผลติดเชื้อ การติดเชื้อทางเดินปัสสาวะ ภาวะแทรกซ้อนจากทางเดินหายใจ ภาวะแทรกซ้อนจากระบบหัวใจและหลอดเลือด หรือ การที่ต้องมาผ่าตัดซ้ำ หลังผ่าตัดมีผู้ป่วย 1 รายตั้งครรภ์ (ร้อยละ 9.1)

สรุป: การผ่าตัดผ่านกล้องเพื่อเอาเนื้องอกมดลูกออกต้องอาศัยทักษะในการผ่าตัดขั้นสูง การประเมินคนไข้ก่อนทำการผ่าตัดเป็นสิ่งสำคัญ จากประสบการณ์การผ่าตัดที่โรงพยาบาลศรีนครินทร์ การผ่าตัดผ่านกล้องเพื่อเอาเนื้องอกมดลูกออก

Objective: To evaluate the intraoperative and postoperative outcomes of laparoscopic myomectomy in Srinagarind Hospital.

Methods: Retrospective data regarding laparoscopic myomectomy were collected between July 2018 and June 2019 from the hospital operating room records and the histopathology database. We found records of 11 women who had undergone laparoscopic myomectomy using a similar technique and examined their demographic data (age, body weight, height, parity), presenting symptoms, preoperative GnRH agonist used, and operative details such as type and number of myomas, size of the largest myoma, and perioperative and postoperative outcomes.

Results: The mean age \pm SD and mean BMI \pm SD were 35.5 \pm 5.1 years and 22.7 \pm 3.7 kg/m², respectively. The most common indications were hypermenorrhea and dysmenorrhea/pelvic pain. The procedure was completed laparoscopically in 10 of the 11 women (90.9%). The mean amount of intra-operative blood loss \pm SD and the mean operative time \pm SD were 320.0 \pm 249.8 ml. and 155.4 \pm 23.4 minutes, respectively. The median length of postoperative hospital stay was 3 days (IQ 3-4). No postoperative complications, such as surgical site infection, urinary tract infection, pulmonary complications, cardiac complications, or reoperation, were noted. One of the patients became pregnant after the procedure (9.1%)

Conclusions: Laparoscopic myomectomy is a minimally invasive procedure that requires advanced

*Corresponding author : Teerayut Temtanakitpaisan, Department of Obstetrics and gynecology, Faculty of Medicine, Khon Kaen University, Khon Kaen, Thailand E-mail: jacktemtanakitpaisan@hotmail.com

ถือว่าเป็นการผ่าตัดที่มีประสิทธิภาพและปลอดภัยเพื่อรักษาผู้ป่วยที่ต้องการเก็บมดลูกเอาไว้

คำสำคัญ: การผ่าตัดผ่านกล้องเพื่อเอาเนื้องอกมดลูกออก ผลลัพธ์ขณะทำการผ่าตัด ผลลัพธ์หลังการผ่าตัด

skills. Preoperative evaluation is important in deciding the type of procedure to be performed. In our experience, laparoscopic myomectomy is safe and is effective in preserving the uterus.

Keywords: Laparoscopic myomectomy, intraoperative outcomes, Postoperative outcomes

ศรีนครินทร์เวชสาร 2562; 34(5): 422-426. • Srinagarind Med J 2019; 34(5): 422-426.

Introduction

Uterine leiomyoma is the most commonly benign uterine tumor found in women of reproductive age. It is approximately 70% of uterine tumor.¹ The pathophysiology of the disease is unknown. Intrinsic myometrial cell abnormality, changes to the estrogen receptor in the myometrium, hormonal changes, or alterations in ischemic response may be responsible for the epigenetic changes.² Most uterine leiomyomas are discovered on clinical examination and asymptomatic. However, in some cases, myomas may cause abnormal uterine bleeding, pelvic pressure, lower back pain, increased urinary frequency, urgency, urinary retention, bowel dysfunction, constipation, subfertility, and dyspareunia.³ Treatment depends on the size and the location of the myomas. In patients who want to preserve the uterus, the myomas are frequently removed via a hysteroscopic or an abdominal route (laparotomy or laparoscopy).⁴

Laparoscopic myomectomy, first performed in 1977, is a minimally invasive procedure to remove myomas. The procedure results in less postoperative pain, a lower rate of postoperative febrile morbidity, shorter hospital stays, quicker recovery time than traditional open myomectomy. However, the laparoscopic approach takes a longer time to perform.⁴ The number and size of the myomas are factors to consider when determining the route of operation. Laparoscopic myomectomy is preferable in cases in which there are a fewer myomas while an open procedure is appropriate in cases in which there are multiple large myomas.⁴

In addition to advanced surgical skill, the success of laparoscopic myomectomy also depends on patient selection.⁴ We thus present our experience with laparoscopic myomectomy in a tertiary hospital's minimally invasive surgery (MIS) unit.

The primary objective of this study was to evaluate intraoperative and postoperative outcomes in cases of laparoscopic myomectomy at Srinagarind

hospital.

Materials and Methods

Retrospective data were collected from the hospital operating room records and histopathology database of laparoscopic myomectomies conducted by Amornrat Temtanakitpaisan and Teerayut Temtanakitpaisan between July 2018 and June 2019. Patient demographic data (age, body weight, height, parity), presenting symptoms, preoperative GnRH agonist used, and operative details, such as type and number of myomas, size of the largest myoma, and perioperative and postoperative outcomes such as the amount of blood loss, the operative time, length of hospital stay, blood transfusion rate and complications after surgery, were examined.

Preoperative GnRH agonist was considered in case of having heavy menstrual bleeding or large size of myoma.

In all cases, laparoscopic myomectomy was conducted using a similar technique under general anesthesia. After catheterization, a uterine manipulator was applied (Pelosi uterine manipulator). Four ports were created at the abdomen: one port, 10 mm in vertical length, at the umbilicus for the 10-mm telescope, two 5 mm ports on the left side and one 5 mm port on right side. The surgeon operated at the left side of the patient. This allowed for the operation to be conducted in a parallel manner, which allowed for a more comfortable and ergonomic position for the surgeon. In cases with large uteri, the ancillary ports were adjusted at the operator's discretion. Initially, a scissors or hook monopolar with 50-watt cutting was applied at the prominent part of the myoma and a transverse incision was made without vasopressin injection (due to it not being available in Thailand). Then we used an advanced bipolar energy device (LigaSure™; Covidien, USA) in combination with mechanical manipulation to enucleate the myomas by using

tenaculum or myoma screw. If the endometrial cavity was breached, the monofilament absorbable sutures were used to repair the endometrial cavity before suturing the myometrium with barbed sutures No 1 (1-2 layers depending the depth of the remaining myometrium). The serosa was closed separately using monofilament absorbable sutures No 2-0 with continuous without lock, as shown in Figure 1. The myomas were morcellated in the bag using a manual technique via the 10 mm umbilical port. Antiadhesive gel or barrier was applied in all cases after hemostatic control. The umbilical incision was closed separately, the rectus sheath was closed with simple interrupted, and the skin was closed using a subcuticular technique. The other 5 mm ports were closed using a subcuticular suture.

For hemostatic control, we used misoprostol 800 micrograms rectal suppository and tranexamic acid 1gram intravenous injection during the operation.

The total amount of blood loss was determined by the operating anesthesiologist based on the contents of the suction containers. Monitoring of hemoglobin and hematocrit levels depended on the surgeon's consideration. The urinary catheter was removed the next day after the operation, and the patients were allowed to return home if they had recovered and were able to eat without discomfort.

Statistical analysis

All collected data were kept confidential. Statistical analysis was performed using SPSS version 13.0. Normality testing was conducted using a Kolmogorov-Smirnov test. Demographic data is shown as percentage, mean (for parametric data) or median (for non-parametric data), and minimum and maximum range.

Results

Approval was attained from the Khon Kaen ethic committee. During the study period, TA and TT performed laparoscopic myomectomy on a total of 11 patients. The mean age ± SD and mean BMI ± SD were 35.5 ± 5.1 years and 22.7 ± 3.7 kg/m², respectively. All of the women were of reproductive age, and ten were nulliparous has undergone laparoscopic myomectomy (90.9%). The indications for surgery are shown in Table 1. The most common indication was hypermenorrhea and dysmenorrhea/pelvic pain. Six (54.5%) of the women received

intramuscular 3.75 mg of GnRH agonist every 1 month for 3-6 months before the operation to reduce their symptoms and the size of the myomas.

The myoma was intramural in 63.6% of the cases and subserous in 9.1%, and there were multiple myomas in the remaining 27.3%. There was only one myoma in seven (63.6%) of the cases. The maximum number of myomas was 9 (9.1%), and the largest myoma (intramural) was 12 cm in diameter. There were four cases (36.4%) of concomitant surgery. Two cases had adhesion, requiring more time for lysis, and another two had undergone laparoscopic ovarian cystectomy due to the presence of an endometriotic cyst. All myomas were removed via the umbilical port by manual in-bag morcellation using a scalpel to decrease the risk of myoma tissue dissemination into the abdominal cavity.

The procedure was completed laparoscopically in 10 of the 11 women (90.9%). One case had dense adhesion to the mesenteric vessels, requiring open myomectomy. The endometrial cavity was breached in two cases (18.2%).

The mean amount of intra-operative blood loss ± SD and the mean operative time ± SD were 320.0 ± 249.8 ml and 155.4 ± 23.4 minutes, respectively. The median length of postoperative hospital stay was

Table1 Indications for laparoscopic myomectomy N=11

Symptoms	n (%)
-Hypermenorrhea	3 (27.3)
-Hypermenorrhea and dysmenorrhea	2 (18.2)
-Hypermenorrhea and infertility	1 (9.0)
-Infertility	2 (18.2)
-Dysmenorrhea /pelvic pain	3 (27.3)

Table 2 Operative outcomes N=11

Operative outcomes	n (%)
Blood loss: mean ± SD	320.0 ± 249.8 ml
Duration of surgery, mins: mean ± SD	155.4 ± 23.4 minutes
Duration of inpatient stay, day (IQR)	3 days (IQ 3-4)
Blood transfusion: n(percent)	1 (9.1%)

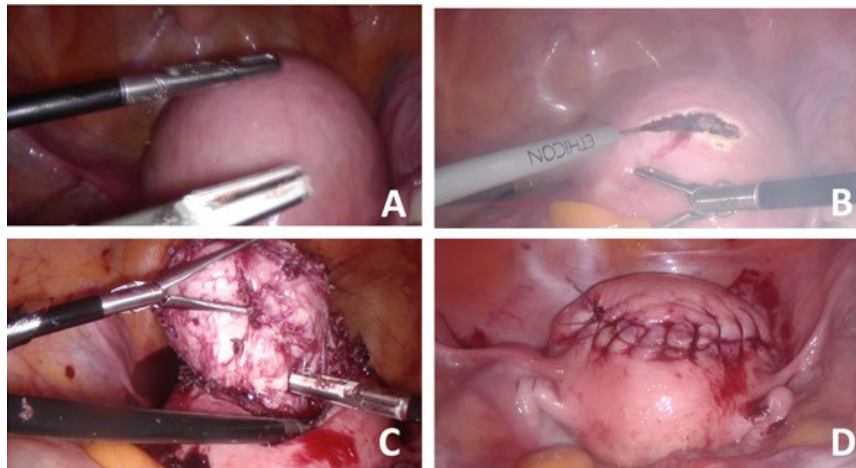


Figure 1 Laparoscopic myomectomy was performed in a patient with intramural myoma at the anterior uterine wall (A). First, a transverse incision was made using a monopolar hook (B) then the myoma was enucleated (C). After complete enucleation, the uterine defect was closed in two layers and the uterine serosa was closed separately using monofilament absorbable sutures with continuous without lock (D).

3 days (IQ 3-4). In one case, the patient received a blood transfusion on postoperative day 1 due to the low level of baseline hemoglobin before surgery caused by hypermenorrhea which was not related with intraoperative blood loss as shown in Table 2. No postoperative complications, such as surgical site infection, urinary tract infection, pulmonary complications, or cardiac complications, were noted. None of the patients underwent reoperation or readmission. One patient became pregnant after the procedure (9.1%).

Discussion

We report our experience over one year after having initiated laparoscopic myomectomy at Srinagarind Hospital. This procedure is considered to be minimally invasive but requires advanced suturing and knot-tying skills.

Preoperative assessment of the number of myomas is essential when determining whether to use this minimally invasive technique or perform an open myomectomy. However, there is no consensus regarding the criteria that should be used to make this determination. Bean EMR et al.⁴ recommend performing laparoscopic surgery in women with < 3 intramural/submucous myomas and a dominant myoma approximately 5-12 cm in diameter. They also emphasize that, in cases of subserous myomas, the abdominal cavity must be large enough to safely perform the minimally invasive procedure. In our study, the largest myoma was approximately 12 cm (intramural) and the maximum number of myomas was nine. In the case in which there were nine myomas,

only two were intramural (4 cm), and seven were small subserous myomas (1-2 cm in diameter), which allowed them to be removed laparoscopically.

The mean amount of intra-operative blood loss in our study was 320.0 ± 249.8 ml, which was higher than in previous reports. A retrospective review of 514 patients⁴ in a single high-volume surgery center revealed the median amount of blood loss from laparoscopic myomectomy was 73 ml (range, 5-3,000 ml). The reason for this disparity might be due to the surgeons in the previous study being more skilled than those in our study and the administration of synthetic vasopressin to the myometrium, which has been proven to reduce blood loss during surgery as well as the blood transfusion rate.⁵ As no vasopressin analogue is available in Thailand, we used misoprostol (800 micrograms; rectal suppository) and antifibrinolytic agents to reduce blood loss during operation. A GnRH agonist (Leuprolide acetate) was used preoperatively in 54.5% of the cases in our study in order to relieve bleeding and decrease the size of myomas. This was based on a systematic review and meta-analysis published in 2011,⁶ which showed administration of GnRH agonists before laparoscopic myomectomy to be beneficial. Moreover, the GnRH agonist was also used to decrease blood loss during the operation.

Uterine defect repair after myoma evacuation should be closed in multiple layers⁷. Therefore, we used barbed suture to close the uterine defect in two layers and the serosa was closed with monofilament absorbable material with continuous without lock. Anti-adhesion gel (hyaluronic acid) was applied over

the repaired myometrium in all cases to prevent adhesion formation.

We removed the myomas via in-bag morcellation with a scalpel at the umbilical port to limit the spread of occult malignancy cells and protect against the development of parasitic leiomyoma. This removal technique came into widespread use after an FDA warning in 2014 regarding power morcellator use and the spread of occult malignancy.⁷

The median length of postoperative hospital stay in our study was 3 days (IQ 3-4), which similar to that in a study by Bean EMR et al.⁴ This is indicative of the fact that laparoscopic procedures result in shorter hospital stays than open surgery. This technique also results in less postoperative pain, faster recovery, and faster return to daily life activities.⁸

Regarding complications, the operation in one case had to be converted to open myomectomy because of unexpected dense adhesion between the myoma and mesentery. However, there were no other postoperative complications, such as surgical site infection, urinary tract infection, pulmonary complications, cardiac complications, or reoperation. The largest case series from Italy⁹ found the major complication rate in 2020 laparoscopic myomectomies to be 2.02%, which is similar to that found in another series (3.5%) that included 514 patients.⁴

This study is a preliminary report regarding the experience of laparoscopic myomectomy in Srinagarind hospital for one year, therefore, the number of patients was limited. However, further study with a larger sample size should be conducted.

Conclusion

Laparoscopic myomectomy is a minimally invasive procedure that requires advanced skill. Preoperative evaluation is important in determining the type of procedure to conduct.

In our experience, laparoscopic myomectomy is a safe and effective procedure for preserving the uterus.

References

1. Liu L, Li Y, Xu H, Chen Y, Zhang G, Liang Z. Laparoscopic transient uterine artery occlusion and myomectomy for symptomatic uterine myoma. *Fertil Steril* 2011; 95: 254–8.
2. Lagana AS, Vergara D, Favilli A, La Rosa VL, Tinelli A, Gerli S, et al. Epigenetic and genetic landscape of uterine leiomyomas: a current view over a common gynecological disease. *Arch Gynecol Obstet* 2017; 296: 855–67.
3. De La Cruz MSD, Buchanan EM. Uterine Fibroids: Diagnosis and Treatment. *Am Fam Physician* 2017; 95: 100–7.
4. Bean EMR, Cutner A, Holland T, Vashisht A, Jurkovic D, Saridogan E. Laparoscopic Myomectomy: A Single-center Retrospective Review of 514 Patients. *J Minim Invasive Gynecol* 2017; 24: 485–93.
5. Cohen SL, Senapati S, Gargiulo AR, Srouji SS, Tu FF, Solnik J, et al. Dilute versus concentrated vasopressin administration during laparoscopic myomectomy: a randomised controlled trial. *BJOG Int J Obstet Gynaecol* 2017; 124: 262–8.
6. Chen I, Motan T, Kiddoo D. Gonadotropin-releasing hormone agonist in laparoscopic myomectomy: systematic review and meta-analysis of randomized controlled trials. *J Minim Invasive Gynecol* 2011; 18: 303–9.
7. Glaser LM, Friedman J, Tsai S, Chaudhari A, Milad M. Laparoscopic myomectomy and morcellation: A review of techniques, outcomes, and practice guidelines. *Best Pract Res Clin Obstet Gynaecol* 2018; 46: 99–112.
8. Bhave Chittawar P, Franik S, Pouwer AW, Farquhar C. Minimally invasive surgical techniques versus open myomectomy for uterine fibroids. *Cochrane Database Syst Rev* 2014; CD004638.
9. Sizzi O, Rossetti A, Malzoni M, Minelli L, La Grotta F, Soranna L, et al. Italian multicenter study on complications of laparoscopic myomectomy. *J Minim Invasive Gynecol* 2007; 14: 453–62.

